

# Management of an injured accessory hepatic duct during laparoscopic cholecystectomy: The importance of operative cholangiography

Hayden Andrew Snow, Aqiq Tulip Chowdhury, Hai Thanh Bui

## ABSTRACT

**Introduction:** We present a case of intra-operative bile duct injury during laparoscopic cholecystectomy. Commonly, this complication would require conversion to an open procedure for repair or biliary-enteric reconstruction. We also review the definitions and implications of extra-hepatic bile duct anomalies. **Case Report:** A 30-year-old female undergoing laparoscopic cholecystectomy sustained an intraoperative bile duct injury, suspicious for the right posterior sectoral duct. However, with the employment of operative cholangiography via the injured duct, it was then able to be identified as accessory, rather than aberrant. The duct could then be ligated and divided, and the procedure could be completed laparoscopically without complication. **Conclusion:** This case serves as an example of the utility of operative cholangiography, especially when encountering unexpected extrahepatic biliary anatomy. Operative cholangiography allowed safe division of an anomalous hepatic duct and completion of the procedure laparoscopically.

**Keywords:** Bile Ducts, Extrahepatic cholangiography cholecystectomy, Laparoscopic

## How to cite this article

Snow HA, Chowdhury AT, Bui HT. Management of an injured accessory hepatic duct during laparoscopic cholecystectomy: The importance of operative cholangiography. J Case Rep Images Surg 2015;1:1–4.

Article ID: 100001Z12HS2015

\*\*\*\*\*

doi:10.5348/Z12-2015-1-CR-1

## INTRODUCTION

Extrahepatic bile duct injury during laparoscopic cholecystectomy is a challenging problem and often requires open conversion with either direct repair or biliary-enteric reconstruction. Anomalous extrahepatic biliary anatomy (along with acute inflammation and contracted gallbladders) is a recognized risk factor for bile duct injury during cholecystectomy [1]. The incidence of anatomical anomalies in the extrahepatic biliary tree is reported between 1.7–28% [2]. Many different anomalous variants are known. Particularly at risk during laparoscopic cholecystectomy, the right posterior sectoral duct can have anomalous insertion into either the common hepatic duct or the cystic duct in 2–5% of cases [3].

## CASE REPORT

A 30-year-old female presented to the emergency department with one day of severe right upper quadrant pain radiating to the back with associated vomiting. She had suffered four similar episodes over the preceding

Hayden Andrew Snow<sup>1</sup>, Aqiq Tulip Chowdhury<sup>1</sup>, Hai Thanh Bui<sup>2</sup>

**Affiliations:** <sup>1</sup>MBBS, Surgical Registrar, Department of General Surgery, Western Health, Footscray, Victoria, Australia; <sup>2</sup>MBBS FRACS, Upper GI Surgeon, Department of General Surgery, Western Health, Footscray, Victoria, Australia.

**Corresponding Author:** Hayden Andrew Snow, Western Health, Gordon St, Footscray, Victoria 3011, Australia; Ph: +61 408844227; Email: hayden.snow2@wh.org.au

Received: 27 April 2015  
Accepted: 29 June 2015  
Published: 10 July 2015

few months and biliary colic was suspected. A biliary ultrasound (arranged by her family doctor nine days prior to presentation) demonstrated multiple mobile calculi in a non-inflamed gallbladder. Laboratory examination upon presentation revealed positive Murphy's sign with a raised white cell count ( $12.7 \times 10^9/L$ ). A diagnosis of calculous cholecystitis was made.

The following day she proceeded to laparoscopic cholecystectomy. Operative findings were a thin-walled, distended gallbladder. Intraoperative cholangiography revealed two filling defects in the distal common bile duct consistent with calculi. In preparation for transcystic choledochoscopy to remove the calculi, distal dissection of the cystic duct was performed. At this point, a tubular structure arising from the hilum, joining the cystic duct, was identified leaking bile in the region of dissection, concerning for injury to the right posterior sectoral hepatic duct (Figure 1), likely caused by diathermy injury.

Repeat operative cholangiography was performed, this time via the injured duct. This revealed contrast opacification of the complete intrahepatic biliary tree via an accessory hepatic duct that appeared to drain into the right posterior sectoral duct (Figure 2). The right posterior sectoral duct also drained into the common hepatic duct via the usual channels (Figure 3). Having confirmed the adequacy of drainage of the affected segment of liver, the injured duct could be safely clipped and divided.

Subsequent attempt at choledochoscopy was unsuccessful and transcystic exploration was aborted. Final operative cholangiogram via the cystic duct showed triple-duct confluence but otherwise normal intrahepatic anatomy and the aberrant duct was clipped with no leak. A drain was left in the gallbladder fossa. Postoperative Computed tomography cholangiography showed no leak from the clipped accessory duct (Figure 4) and no common duct calculi. Her recovery was unremarkable and was discharged on postoperative day-2 with normal liver function.

## DISCUSSION

Accessory hepatic ducts are anomalous ducts that drain individual segments of liver [4]. They usually drain from the right hepatic lobe to the biliary tree anywhere from the hepatic hilum to the cystic duct [5] and occur in between 1–31% of patients [6]. Depending on the additional drainage of the involved segment of liver, these ducts may be truly 'accessory' or 'aberrant'. If the duct is the sole drainage to that segment, the duct is 'aberrant'. If, however, that segment has drainage via the right hepatic duct in addition to the accessory duct, the duct is 'accessory' [7]. We have described a case of accessory hepatic duct injury encountered during laparoscopic cholecystectomy and the use of operative cholangiography in defining and managing the anomalous anatomy.

Identification and anatomical delineation of injured hepatic ducts is essential in determining appropriate

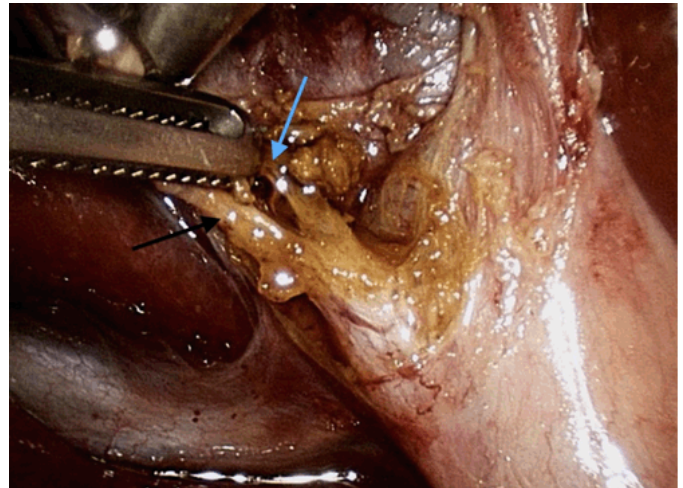


Figure 1: Operative photo showing cystic duct (black arrow) and a hole in the aberrant duct (blue arrow).

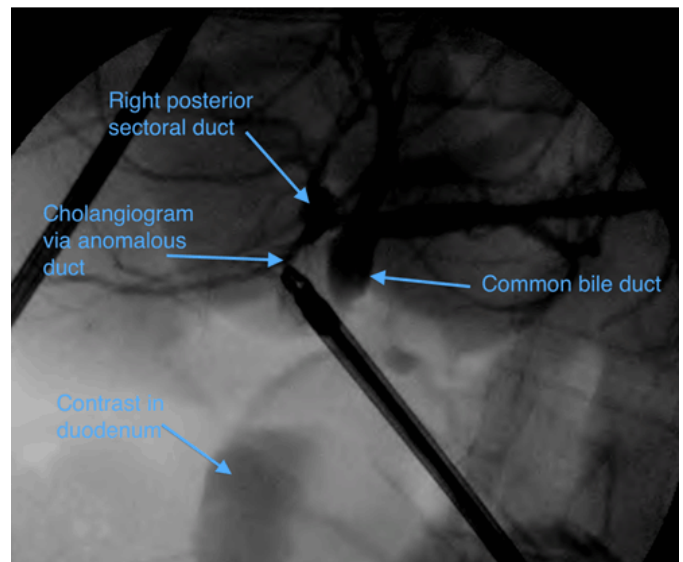


Figure 2: Operative cholangiogram via injured duct (note limited opacification of common bile duct due to compression from cholangiogram catheter and low pressure generated via accessory duct).

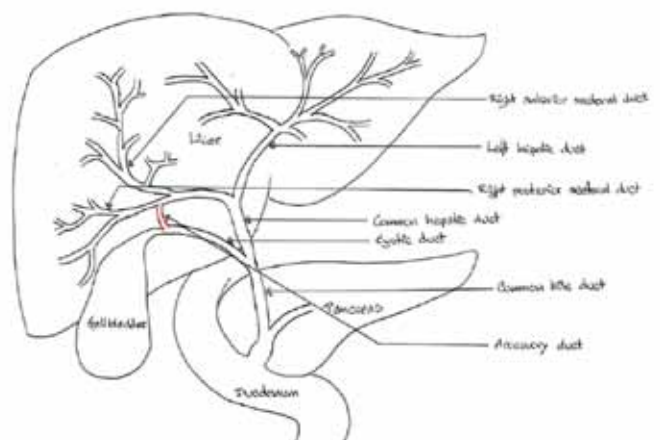


Figure 3: Schematic diagram showing site of accessory duct (red).

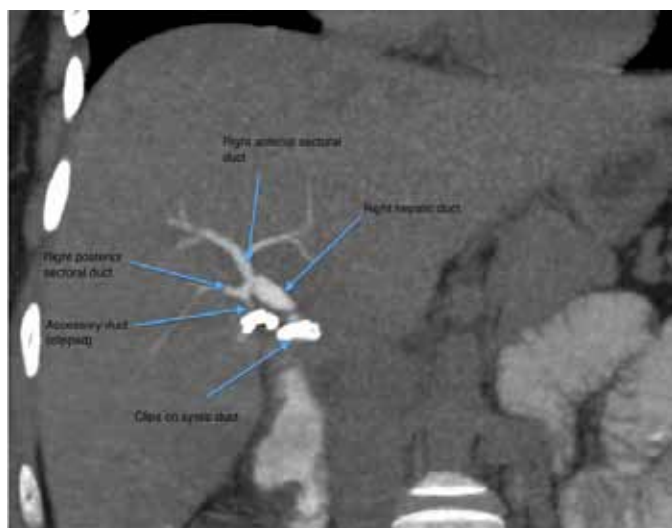


Figure 4: Postoperative computed tomography cholangiogram showing accessory duct clipped.

operative management. Aberrant ducts, if divided, need to be repaired directly or with a biliary-enteric reconstruction to prevent obstruction-related atrophy, as the drained liver segment has no alternate outflow. This is especially important if the injured duct is major, like the right posterior sectoral duct. Accessory ducts, however, may be divided and ligated, as the affected liver segment will continue to drain via its other duct.

A thorough knowledge of the anatomy of the extrahepatic biliary tree and its variations is essential in interpreting cholangiography. Failure to recognize aberrant ducts can lead to either injury, ligation or post-operative bile leak. Postoperative computed tomography cholangiography or ERCP may be useful for diagnosis and treatment in these scenarios. However, ERCP and insertion of biliary stents is often not effective in controlling bile leak from injured aberrant ducts.

Our case highlights the importance and utility of operative cholangiography in this setting. If the aberrancy is recognized, cholangiography via the injured duct can assess the size and alternate drainage (if any) of the affected segment of liver and direct appropriate treatment. In our case, identification of the injured duct as accessory, and confirming the other ducts intact (particularly the right posterior sectoral duct), allowed confident ligation laparoscopically and completion of the cholecystectomy.

## CONCLUSION

We have described a case involving the challenging complication of bile duct injury during laparoscopic cholecystectomy. This was successfully managed with the use of operative cholangiography through the injured duct, identifying the duct as accessory and allowing safe division of the duct laparoscopically. Operative

cholangiography should be used in all cases where ductal anatomy requires delineation to proceed safely. As it can be readily performed laparoscopically, it can allow safe completion of more complicated cases of aberrant or accessory extrahepatic biliary anatomy laparoscopically without the need for open conversion.

\*\*\*\*\*

## Author Contributions

Hayden Andrew Snow – Substantial contributions to conception and design, Acquisition of data, Drafting the article, Revising it critically for important intellectual content, Final approval of the version to be published

Aqiq Tulip Chowdhury – Substantial contributions to conception and design, Acquisition of data, Analysis and interpretation of data, Drafting the article, Final approval of the version to be published

Hai Thanh Bui – Substantial contributions to conception and design, Revising it critically for important intellectual content, Final approval of the version to be published

## Guarantor

The corresponding author is the guarantor of submission.

## Conflict of Interest

Authors declare no conflict of interest.

## Copyright

© 2015 Hayden Andrew Snow et al. This article is distributed under the terms of Creative Commons Attribution License which permits unrestricted use, distribution and reproduction in any medium provided the original author(s) and original publisher are properly credited. Please see the copyright policy on the journal website for more information.

## REFERENCES

1. Krähenbühl L, Scwabas G, Wente MN, Schäfer M, Schlumpf R, Büchler MW. Incidence, risk factors, and prevention of biliary tract injuries during laparoscopic cholecystectomy in Switzerland. *World J Surg* 2001 Oct;25(10):1325–30.
2. Kwon AH, Inui H, Imamura A, Uetsuji S, Kamiyama Y. Preoperative assessment for laparoscopic cholecystectomy: feasibility of using spiral computed tomography. *Ann Surg* 1998 Mar;227(3):351–6.
3. Wojcicki M, Patkowski W, Chmurowicz T, et al. Isolated right posterior bile duct injury following cholecystectomy: report of two cases. *World J Gastroenterol* 2013 Sep 28;19(36):6118–21.
4. Lamah M, Dickson GH. Congenital anatomical abnormalities of the extrahepatic biliary duct: a personal audit. *Surg Radiol Anat* 1999;21(5):325–7.
5. Larobina M, Nottle PD. Extrahepatic biliary anatomy at laparoscopic cholecystectomy: is aberrant anatomy important? *ANZ J Surg* 2005 Jun;75(6):392–5.

6. Benson EA, Page RE. A practical reappraisal of the anatomy of the extrahepatic bile ducts and arteries. *Br J Surg* 1976 Nov;63(11):853–60.
7. Nagral S. Anatomy relevant to cholecystectomy. *J Minim Access Surg* 2005 Jun;1(2):53–8.

Access full text article on  
other devices



Access PDF of article on  
other devices

