

CASE REPORT

PEER REVIEWED | OPEN ACCESS

Actinomyces-like *Propionibacterium propionicum* infection associated with use of intrauterine contraceptive device: A case report

Fouzia Memon, Ayesha Anwar, Mohamed Matar, Leon Jonker

ABSTRACT

Introduction: Intrauterine contraceptive devices generally carry a low risk of complications. Infection, possibly due to damage caused upon insertion, can occur and actinomycetaceae are the most likely cause of pelvic actinomyces. **Case Report:** A 41-year-old female presented with a two-month history of raised temperature, weight loss and abdominal tenderness. Contrast tomography imaging indicated pyometria and pelvic actinomyces-like abscess linked to intrauterine contraceptive device use. Full microbiological reporting, including anaerobic cultures and 16S PCR, identified the bacterium *Propionibacterium propionicum*. A six-month course of amoxicillin resolved the infection and the patient made a full recovery. **Conclusion:** Increased IUCD-related actinomyces awareness and improved diagnostics may increase detection of *P. propionicum*, a pathogen rarely reported on to date.

Keywords: Intrauterine contraceptive device, Pelvic abscess, *Propionibacterium propionicum*, Pyometria

How to cite this article

Memon F, Anwar A, Matar M, Jonker L. Actinomyces-like *Propionibacterium propionicum* infection associated with use of intrauterine contraceptive device: A case report. J Case Rep Images Gynecol Obstet 2016;2:57–60.

Article ID: 100020Z08FM2016

doi:10.5348/Z08-2016-20-CR-13

INTRODUCTION

The use of Intrauterine contraceptive devices (IUCD) does carry a risk of infection; actinomycetaceae are the most likely cause of pelvic actinomyces [1–3]. Some case reports and case series have described actinomyces, and it has been suggested that the incidence of this complication is higher than generally thought [3, 4]. Pyometria and pelvic actinomyces-like abscess due to *Propionibacterium propionicum* (formerly known as *Arachnia propionica*) is, however, an even rarer occurrence. To date, only a few case report publications have reported such instances with only one showing positive culture of the anaerobe *P. propionicum* which normally resides in sweat glands and on the skin [5–7]. Here we report a case of pyometria and pelvic actinomyces-like abscess, linked to an in situ intrauterine contraceptive device.

CASE REPORT

A 41-year-old female, para 2, admitted to hospital for right iliac fossa pain, plus reduced appetite and weight

Fouzia Memon¹, Ayesha Anwar¹, Mohamed Matar¹, Leon Jonker²

Affiliations: ¹North Cumbria University Hospitals NHS Trust, Department of Obstetrics & Gynaecology, Cumberland Infirmary, Carlisle, CA2 7HY, UK; ²PhD, University of Cumbria, Faculty of Health & Wellbeing, Carlisle, CA1 2HH, UK.

Corresponding Author: Dr. Leon Jonker, PhD, Honorary Research Fellow, North Cumbria University Hospitals NHS Trust, Department of Obstetrics and Gynaecology, Cumberland Infirmary, Carlisle, CA2 7HY, UK.

Received: 07 July 2016
Accepted: 17 July 2016
Published: 29 August 2016

loss, that had been present for two months. Furthermore, the patient had generalized tenderness in lower abdomen. Observations showed normal blood pressure and pulse, but raised temperature of 37.8°C. Computed tomography scan revealed bilateral predominantly cystic ovarian masses with solid component, plus multiple peritoneal nodules with pelvic free fluid (Figures 1 and 2).

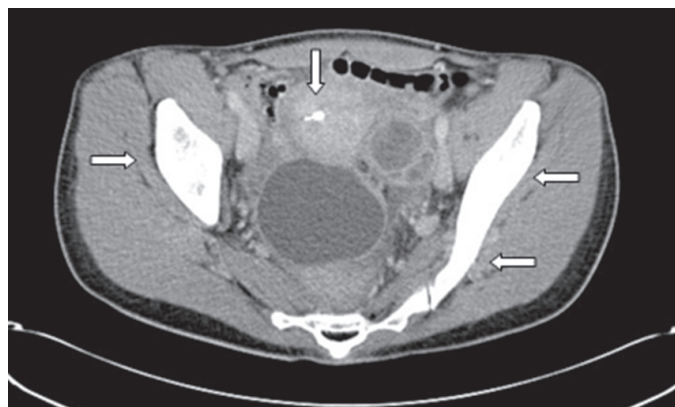


Figure 1: Axial computed tomography imaging of patient, upon admission to hospital. The bilateral cystic ovarian masses are visualized and the IUCD can be seen in the endometrial cavity.

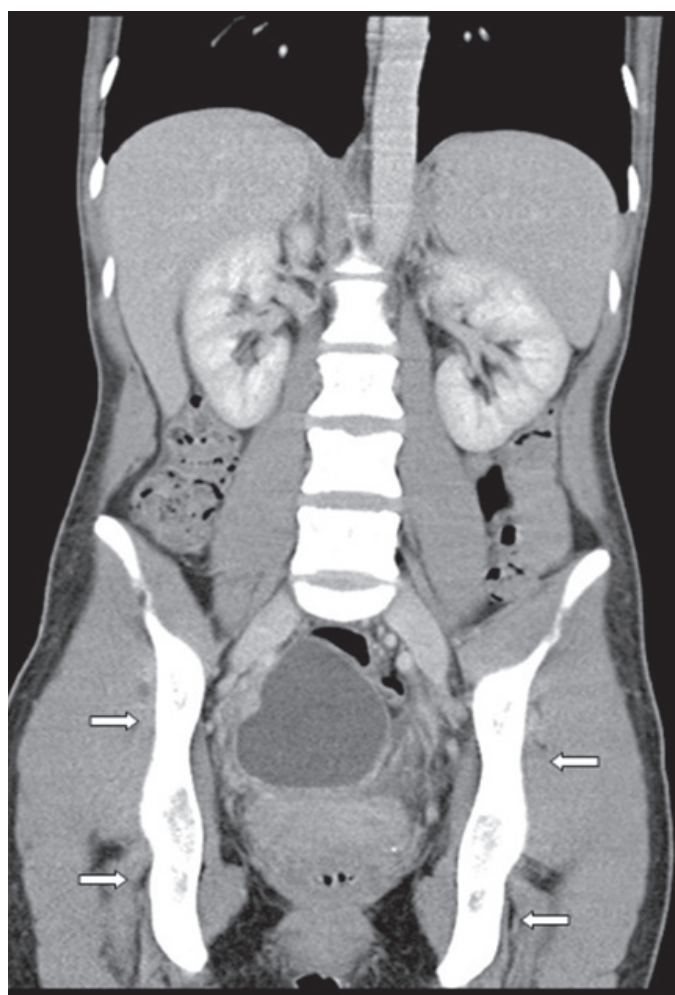


Figure 2: Coronal computed tomography scan of patient, upon admission to hospital. Infection has spread bilaterally in the ovaries and large areas of the pelvis.

Ultrasound of the abdomen and pelvis showed a normal-sized anteverted uterus with an IUCD in situ within the endometrial cavity. It confirmed earlier CT scan findings regarding bilateral complex adnexal cysts; measurements were 70x63x61 mm (right) and 63x48x54 mm (left). The right ovary was separate from the cyst, but the left ovary was not separate from the adnexal cyst. White cell count and C-reactive protein results were only slightly raised $13 \times 10^9/L$ and 119 mg/L respectively, and tumor markers CA125, CEA and CA19-9 were normal.

Due to the case complexity, planned laparoscopy was converted to laparotomy, adhesiolysis, drainage of left ovarian abscess, right mesosalpinx cystectomy, right partial salpingectomy and removal of IUCD. Frank pus exuded from the cervical ostium during the IUCD removal. Tissue and pus specimens were sent for histology and microbiological testing respectively. Histology reporting matched the tumor marker results: benign tissues with chronic inflammatory features.

Gram stain of the original sample showed few pus cells and mixed organisms including actinomyces-like organisms. No growth resulted from direct culture, but the anaerobic five-day culture yielded colonies with a “breadcrumb” appearance and Gram stain showed Gram-positive, long, branching rods (Figure 3). The isolate was given a presumptive identification of “*Actinomyces* species” and referred to an anaerobic reference unit for confirmation and susceptibility testing. There were three anaerobic organisms listed below identified with 16S PCR molecular techniques: *P. propionicum*, *Campylobacter rectus* – both susceptible to penicillin and clindamycin – and *Eikenella corrodens*, resistant to penicillin and clindamycin.

The patient was started on a regime of intravenous amoxicillin (1 gram tid for 6 weeks) followed by oral amoxicillin 1 gram tid for six months. She responded well to amoxicillin and gradually symptoms abated. After six weeks of antibiotic therapy, follow-up CT scan revealed two small fluid collections, which were most likely post-

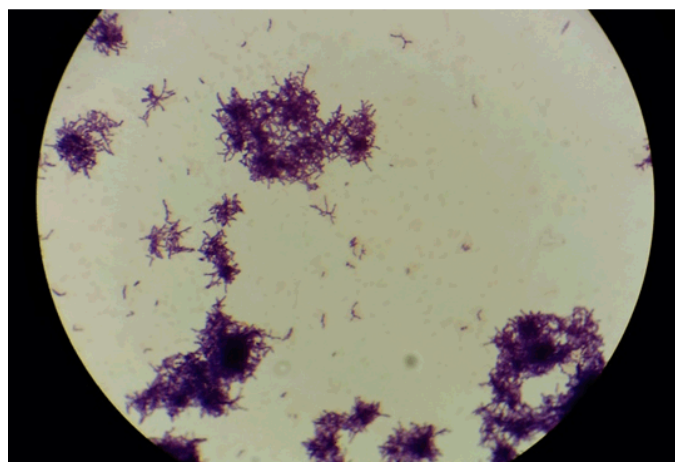


Figure 3: *P. propionicum* culture obtained from patient’s pus sample (magnification x100).

operative and did not warrant drainage. Further notable improvement was noted at sixth-month follow-up visit via computed tomography scan (Figures 4 and 5).

DISCUSSION

To our knowledge, this is the second reported confirmed case of an IUCD-related *P. propionicum* actinomycotic-like pelvic abscess after Wunderink's

report in 2011 [7]. Our patient showed clinical symptoms akin to actinomycotic pelvic abscess: abdominal pain, weight loss and fever. This aided us to form a differential diagnosis and to progress a microbiological investigation. Often, patients with abscess undergo surgery and the result may be hysterectomy or otherwise. Since antibiotic treatment can lead to significant clinical improvements once the exact pathogen has been identified, it is essential to initiate sampling and sensitivity tests promptly. In the past, a Papanicolaou smear has been suggested as a useful adjunct diagnostic tool [4, 8]. Presently, molecular profiling with 16S PCR is a powerful tool for detecting the exact strains present in a pathological specimen.

CONCLUSION

A thorough medical history, including determining whether a patient uses an IUCD, and imaging form the standard diagnostic arsenal for clinicians consulting patients who present with general malaise and abdominal tenderness. Actinomycotic, and actinomycotic-like, pelvic infection may be more common condition than the levels of published data suggest. One study showed that 3% of patients with an IUCD in situ have test positive for actinomycetes infection—some of which were asymptomatic. Therefore, it is prudent to suspect infection in women with IUCD in situ who are symptomatic. Molecular profiling of tissue and pus specimens can further pinpoint the source of infection, and allow tailored antibiotic treatment.

Author Contributions

Fouzia Memon – Substantial contributions to conception and design, Acquisition of data, Analysis and interpretation of data, Drafting the article, Revising it critically for important intellectual content, Final approval of the version to be published

Ayesha Anwar – Analysis and interpretation of data, Revising it critically for important intellectual content, Final approval of the version to be published

Mohamed Matar – Analysis and interpretation of data, Revising it critically for important intellectual content, Final approval of the version to be published

Leon Jonker – Analysis and interpretation of data, Revising it critically for important intellectual content, Final approval of the version to be published

Guarantor

The corresponding author is the guarantor of submission.

Conflict of Interest

Authors declare no conflict of interest.

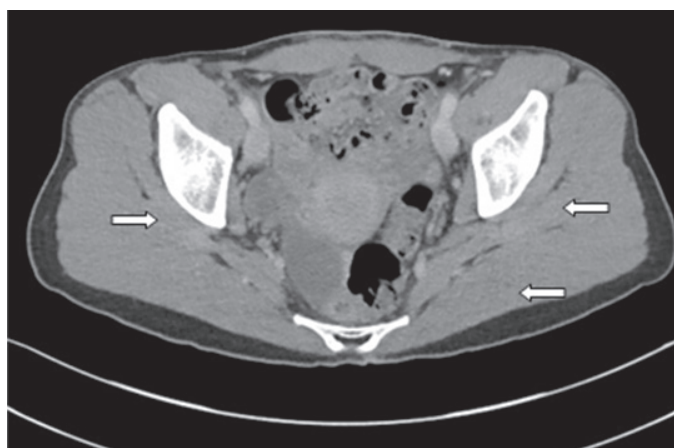


Figure 4: Axial computed tomography imaging of patient, six months into treatment. Lack of ovarian masses and free fluid in pelvis.

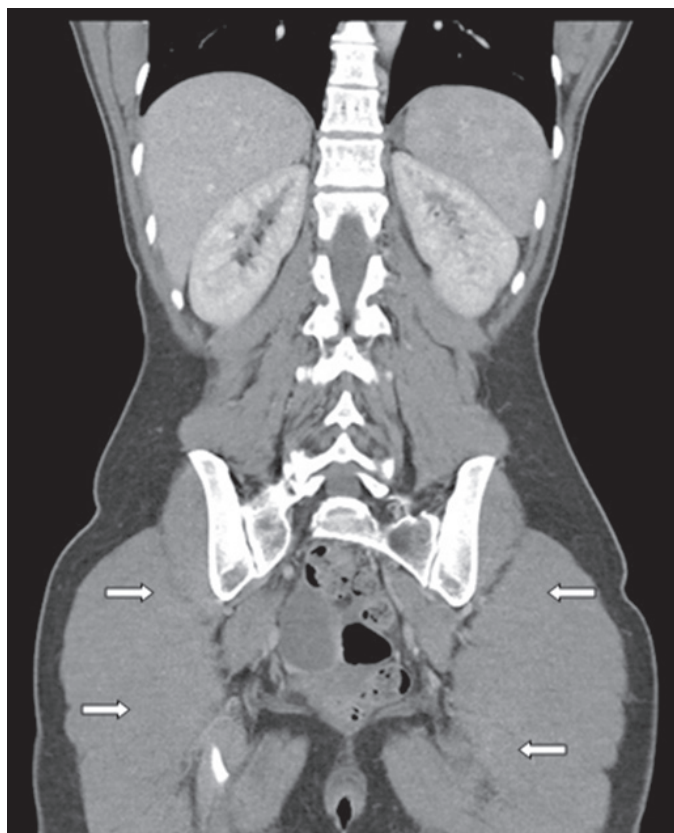


Figure 5: Coronal computed tomography imaging of patient, six months into treatment. The infection, previously present in the ovaries and pelvis, has resolved.

Copyright

© 2016 Fouzia Memon et al. This article is distributed under the terms of Creative Commons Attribution License which permits unrestricted use, distribution and reproduction in any medium provided the original author(s) and original publisher are properly credited. Please see the copyright policy on the journal website for more information.

REFERENCES

1. Brenner RW, Gehring SW. Pelvic actinomycosis in the presence of an endocervical contraceptive device. Report of a case. *Obstet Gynecol* 1967 Jan;29(1):71–3.
2. Henderson SR. Pelvic actinomycosis associated with an intrauterine device. *Obstet Gynecol* 1973 May;41(5):726–32.
3. Schiffer MA, Elguezabal A, Sultana M, Allen AC. Actinomycosis infections associated with intrauterine contraceptive devices. *Obstet Gynecol* 1975 Jan;45(1):67–72.
4. Fiorino AS. Intrauterine contraceptive device-associated actinomycotic abscess and Actinomyces detection on cervical smear. *Obstet Gynecol* 1996 Jan;87(1):142–9.
5. Brock DW, Georg LK, Brown JM, Hicklin MD. Actinomycosis caused by *Arachnia propionica*: Report of 11 cases. *Am J Clin Pathol* 1973 Jan;59(1):66–77.
6. Novak A, Brüttsch P. Case report of actinomycosis caused by *Arachnia propionica*. *Infection* 1980;8 Suppl 2:S209–11.
7. Wunderink HF, Lashley EE, van Poelgeest MI, Gaarenstroom KN, Claas EC, Kuijper EJ. Pelvic actinomycosis-like disease due to *Propionibacterium propionicum* after hysteroscopic removal of an intrauterine device. *J Clin Microbiol* 2011 Jan;49(1):466–8.
8. Nayar M, Chandra M, Chitraratha K, Kumari Das S, Rai Chowdhary G. Incidence of actinomycetes infection in women using intrauterine contraceptive devices. *Acta Cytol* 1985 Mar–Apr;29(2):111–6.

Access full text article on
other devices



Access PDF of article on
other devices

