

CASE REPORT

PEER REVIEWED | OPEN ACCESS

Spontaneous spinal epidural hematoma and acute paralysis secondary to aspirin 81 mg therapy: A case report

Justice Otchere, Scott Russel Strum, Christian Sarfo-Poku

ABSTRACT

Introduction: There are numerous conditions like arterial dissection, blood dyscrasias or coagulopathic disease, trauma, AVM and hematoma that can cause injury to the spinal cord leading to clinical presentation of paresis or plegia. However, there are not frequent reports of aspirin related spinal epidural hematoma. Spinal epidural hematoma is a rare etiology for acute paralysis. **Case Report:** A 47-year-old male with past medical history of hypertension and herniated intervertebral disc who presented to the emergency department with acute onset of mid-axial back pain between his scapulae associated with acute right sided paresis and paresthesia on all extremities. The patient had been on aspirin 81 mg for cardioprotection. He was ruled out for common causes of spinal epidural hematoma. Magnetic resonance imaging (MRI) scan of the cervical spine with and without contrast revealed findings consistent with a right-sided posterolateral epidural hematoma extending from C3–C6. **Conclusion:** The definite pathophysiology of the spinal epidural hematoma is not well established. However, this paper illustrates a case of acute paralysis due to aspirin 81 mg.

Keywords: Arteriovenous malformation, Coagulopathy, Plegia, Spinal cord injury

How to cite this article

Otchere J, Strum SR, Sarfo-Poku C. Spontaneous spinal epidural hematoma and acute paralysis secondary to aspirin 81 mg therapy: A case report. J Case Rep Images Med 2016;2:62–66.

Article ID: 100022Z09JO2016

doi:10.5348/Z09-2016-22-CR-15

INTRODUCTION

Spinal epidural hematoma is rare disease with incident rate of 0.1 patient per 100000 [1]. International frequency is unknown, though it is likely to parallel the frequency in the United States. Epidural hematoma may be intracranial (EDH) or spinal epidural hematoma (SDEH). Spinal epidural hematoma may be acute (58%), subacute (31%), or chronic (11%). Some studies have suggested that spinal EDH occurring spontaneously or after minimal trauma may be attributed most often to a venous vasculature compromise [2, 3]. Some other possible etiologies include coagulopathy, anticoagulation, thrombocytopenia, AV malformation, disk herniation, Paget disease of bone, Valsalva maneuver, and, possibly, hypertension [2–4]. Spinal epidural hematoma may cause severe myelopathy resulting in paresis and sensory deficits depending on the level and extent on the hematoma [5]. The purpose of this paper is to present a case of spontaneous spinal epidural hematoma likely related to chronic aspirin 81 mg therapy.

Justice Otchere¹, Scott Russel Strum¹, Christian Sarfo-Poku²

Affiliations: ¹MD, Loma Linda University Medical Center, Department of Physical Medicine and Rehabilitation; ²MPH, Loma Linda University, School of Medicine

Corresponding Author: Justice Otchere, Loma Linda University Medical Center, Department of Physical Medicine and Rehabilitation; E-mail: jotchere@llu.edu

Received: 28 October 2015
Accepted: 05 December 2015
Published: 05 July 2016

CASE REPORT

A 47-year-old male with past medical history of hypertension and herniated intervertebral disc who presented to the emergency department with acute onset of mid-axial back pain between his scapulae associated with acute right sided paresis and paresthesia on all extremities. An MRI scan of the cervical spine with and without contrast revealed findings consistent with a right-sided posterolateral epidural hematoma extending from C3–C6 with leftward displacement and compression of the thecal sac causing narrowing in the transverse dimension, cord edema, and moderate to severe right-sided neural foramina narrowing. He later had MRI scan of the brain that showed possible cavernoma in the right corona radiata, otherwise normal. His physical examination and diagnostic studies confirmed acute spinal C3–6 epidural hematoma with right sided paresis. He was evaluated by neurosurgery and had posterior cervical laminectomy, decompression (C3-6) for evacuation of hematoma, possible instrumentation and fusion, with intraoperative neuromonitoring (to evaluate for additional spinal myelopathy associated with spinal surgery). His intraoperative monitoring showed absence of motor evoked potentials (MEPs) in the right upper limb and the right lower limb throughout surgery, including baseline correlating with the clinical presentation of right-sided plegia and essentially normal sensation.

Otherwise, he had a stable intraoperative spinal cord monitoring during spinal surgery. His surgical course was uncomplicated and the patient regained some motor function on his right upper and lower extremities. Post-surgical radiological examinations revealed no residual epidural hematoma. Increased signal within the spinal cord at levels C4–C6 is suggestive of cord edema (Figures 1–4). He was then admitted to acute rehab for intensive physical and occupational therapy for regain of some of his functional loss. Functional independence (FIM) scores for ambulation on admission to acute inpatient was moderate assistance with hand held device for 10 ft shuffling, minimal to moderate assistance with hand held assist for 21–30 ft and modified independence with FWW Distance (ft) 401–500 on the day of discharge from acute rehab. His balance and sensation had been within functional limit since the day of admission to discharge.

DISCUSSION

Epidural hematoma usually results from a brief linear contact force to the calvaria that cause separation of the periosteal dura from bone and disruption of interposed vessels due to shearing stress. Spinal epidural hematomas may be either spontaneous or occur as result of a trauma. There are multiple etiologies for spontaneous spinal hematoma among which are thrombolysis, blood dyscrasias, thrombocytopenia, AV malformation, neoplasm and anticoagulation [2–4]. The symptomatic

manifestation of spinal epidural may be rapid or delayed onset depending if the compromised vascular structure is an artery or vein. Epidural hematoma in spinal cord

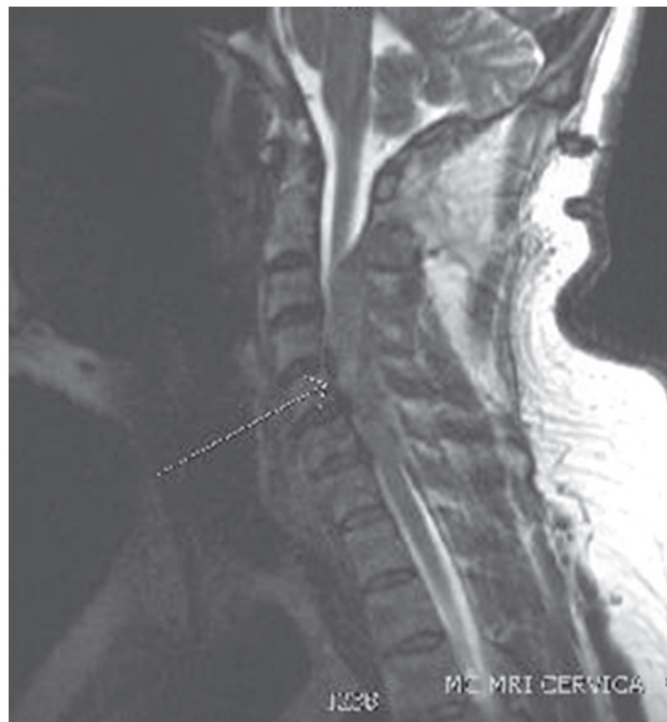

Figure 1: Pre-surgery sagittal cut MRI C-spine.

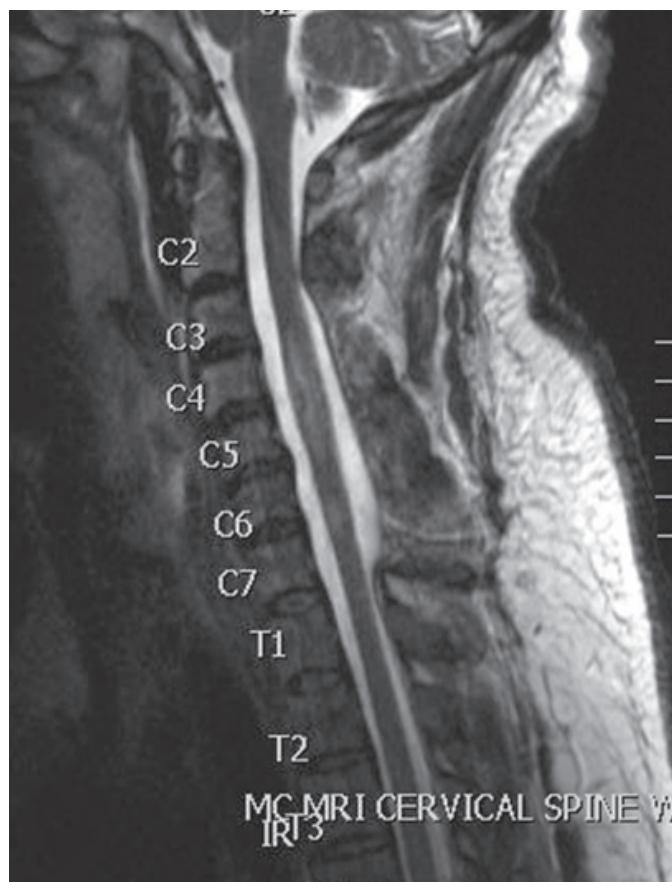


Figure 2: Post-surgery sagittal cut MRI C-spine.

is believed to be of venous origin, however, studies conducted by Beatty and Winston suggests that spinal hematoma originates from arterial origin [6]. A possible pathophysiology for the occurrence of epidural hematoma could be an increase in pressure in the epidural plexus from the retrograde flow in the plexus as result of the lack

of valves in the venous plexus. This phenomenon could be exaggerated during physical exertions, hypertensive emergencies, chronic hypertension or any other activity that increases the systemic blood pressure. Like any other spinal cord injury clinical presentation is dependent on the level and extent of injury [5]. The dorsal aspect of the thoracic or lumbar region is involved most commonly, with expansion limited to a few vertebral level [6]. In this case, the expansion of the hematomas was from the C3-C6 levels.

The patient discussed here denied any trauma to his back prior to the onset of his presentation. He had been on aspirin 81 mg daily for cardioprotection, otherwise he denies any personal history or family history of blood dyscrasias. His platelet at the time of admission was within normal limits. He was taking a beta blocker for optimal blood pressure control and had denied spine interventional procedure. Interventional radiology evaluated his right thyrocervical/common trunk, right vertebral, right subclavian, distal left subclavian, left vertebral and proximal left subclavian arteries for vascular abnormalities. The results of the spinal angiogram revealed a normal cervical spinal angiogram, specifically, no evidence of a vascular anomaly. The patient was ruled out for thrombocytopenia, AV malformation and trauma as possible etiologies of his presentation. An extensive workup for blood dyscrasias was not done given the patient's denial of any pertinent family history or personal history of easy bruising or bleeding. After exclusion of the common possible causes of SEDH in the patient, the conclusion was that aspirin therapy was the most reasonable etiology.

Although, there is no proof of direct correlation in this case, further literature review revealed some cases of aspirin related SDEH [7–13]. Only four of the cases reviewed involved the use of aspirin 81 mg dose, the remaining cases had higher dose [10–13]. Interestingly, Mehta et al. revealed in their studies of bleeding risk on different aspirin doses that there is there no difference in bleeding occurrence between high and low doses [13]. Therefore, it could be inferred that 81 mg aspirin dose could potentially cause an epidural hematoma as illustrated in this patient. Reports of anticoagulation induced spinal epidural hematoma is common, however, anti-platelet causing spinal epidural hematoma is rare [12].

CONCLUSION

Spinal epidural hematoma has several etiologies, however, it is sometimes a challenge to elucidate on its specific etiology if the cause is not trauma, hemorrhage from blood dyscrasias, or vascular abnormalities. There have been studies reporting cases of spontaneous spinal epidural hematoma. However, one should not be satisfied with the mere fact of spontaneity of these incidents as a reasonable answer. The cause of the spinal

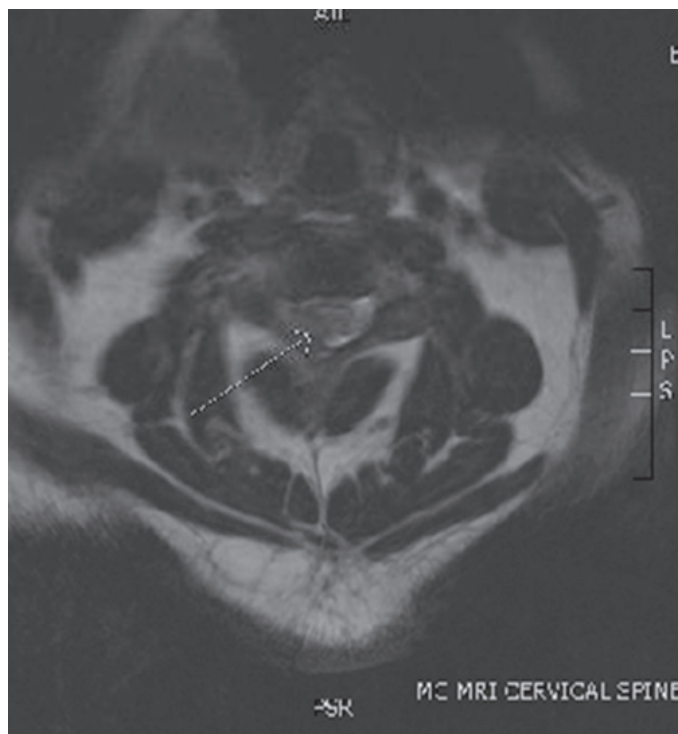


Figure 3: Pre-surgery axial cut MRI C-spine.

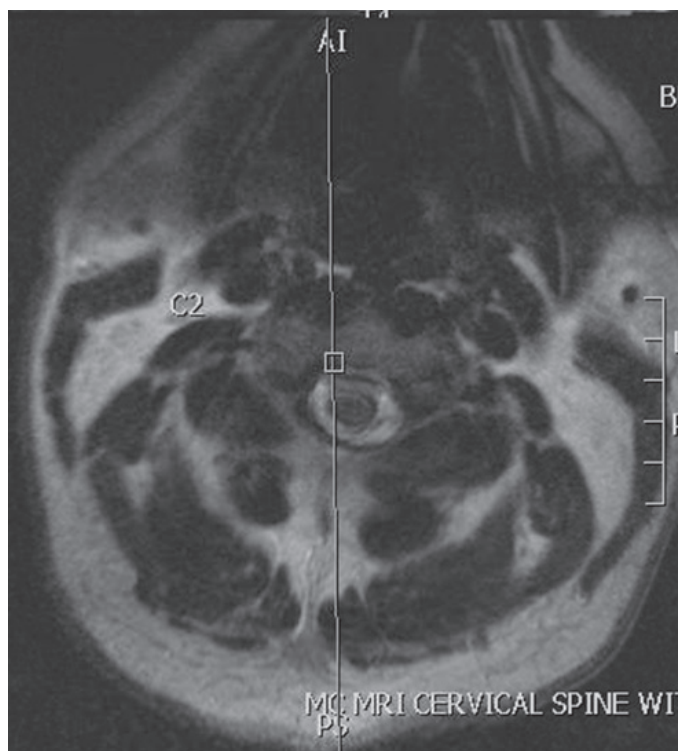


Figure 4: Post-surgery axial cut MRI C-spine. The arrows point to the spinal hematoma pre-evacuation.

epidural hematoma discussed in this patient could be possibly attributed to the use of chronic aspirin therapy. However, there may be other contributory factors that are not accounted for in this paper. We hope to launch further studies in the future with the aim of elucidating the pathophysiology of some of the cases of spontaneous spinal epidural hematoma.

Author Contributions

Justice Otchere – Substantial contributions to conception and design, Acquisition of data, Analysis and interpretation of data, Drafting the article, Revising it critically for important intellectual content, Final approval of the version to be published

Scott Russel Strum – Substantial contributions to conception and design, Acquisition of data, Analysis and interpretation of data, Drafting the article, Revising it critically for important intellectual content, Final approval of the version to be published

Christian Sarfo-Poku – Substantial contributions to conception and design, Acquisition of data, Analysis and interpretation of data, Drafting the article, Revising it critically for important intellectual content, Final approval of the version to be published

Guarantor

The corresponding author is the guarantor of submission.

Conflict of Interest

Authors declare no conflict of interest.

Copyright

© 2016 Justice Otchere et al. This article is distributed under the terms of Creative Commons Attribution License which permits unrestricted use, distribution and reproduction in any medium provided the original author(s) and original publisher are properly credited. Please see the copyright policy on the journal website for more information.

REFERENCES

1. Liu Z, Jiao Q, Xu J, Wang X, Li S, You C. Spontaneous spinal epidural hematoma: analysis of 23 cases. *Surg Neurol* 2008 Mar;69(3):253–60; discussion 260.
2. Groen RJ, Ponssen H. The spontaneous spinal epidural hematoma. A study of the etiology. *J Neurol Sci* 1990 Sep;98(2-3):121–38.
3. Fukui MB, Swarnkar AS, Williams RL. Acute spontaneous spinal epidural hematomas. *AJNR Am J Neuroradiol* 1999 Aug;20(7):1365–72.
4. Panciani PP, Forgnone S, Fontanella M, Ducati A, Lanotte M. Unusual presentation of a spontaneous spinal epidural haematoma. *Acta Neurol Belg* 2009 Jun;109(2):146–8.
5. Bruyn GW, Bosma NJ. Spinal extradural haematoma. In: Vin-ken PJ, Bruyn GW eds. *Handbook of Clinical*

- Neurology. Vol 26. Amsterdam: North-Holland; 1976. p. 1–30.
6. Wisoff HS. Spontaneous intraspinal hemorrhage. In: Wilkins RH, Rengachary SS eds. *Neurosurgery*, 2ed. New York: McGraw-Hill; 1996. p. 2559–65.
7. Locke GE, Giorgio AJ, Biggers SL Jr, Johnson AP, Salem F. Acute spinal epidural hematoma secondary to aspirin-induced prolonged bleeding. *Surg Neurol* 1976 May;5(5):293–6.
8. Mishima K, Aritake K, Morita A, Miyagawa N, Segawa H, Sano K. A case of acute spinal epidural hematoma in a patient with antiplatelet therapy. [Article in Japanese]. *No Shinkei Geka* 1989 Sep;17(9):849–53.
9. Heye N. Is there a link between acute spinal epidural hematoma and aspirin? *Spine (Phila Pa 1976)* 1995 Sep 1;20(17):1931–2.
10. Wagner S, Forsting M, Hacke W. Spontaneous resolution of a large spinal epidural hematoma: case report. *Neurosurgery* 1996 Apr;38(4):816–8.
11. Weber J, Hoch A, Kilisek L, Spring A. Spontaneous intraspinal epidural hematoma secondary to use of platelet aggregation inhibitors. [Article in German]. *Dtsch Med Wochenschr* 2001 Aug 3;126(31-32):876–8.
12. Kim KT, Cho DC, Ahn SW, Kang SH. Epidural Hematoma Related with Low-Dose Aspirin: Complete Recovery without Surgical Treatment. *J Korean Neurosurg Soc* 2012 May;51(5):308–11.
13. Mehta SR, Tanguay JF, Eikelboom JW, et al. Double-dose versus standard-dose clopidogrel and high-dose versus low-dose aspirin in individuals undergoing percutaneous coronary intervention for acute coronary syndromes (CURRENT-OASIS 7): a randomised factorial trial. *Lancet* 2010 Oct 9;376(9748):1233–43.

Access full text article on
other devices



Access PDF of article on
other devices

